

Arthroscopic Treatment of Femoroacetabular Impingement

Thomas G. Sampson, M.D.

Summary: Femoroacetabular impingement (FAI) is a condition that occurs commonly in young adults and middle age that causes hip pain felt mostly in the groin. X-rays often appear "normal" to the untrained observer, however, on careful analysis an anterior to lateral bump may be visualized at the head-neck junction as an extension of the physal line.²⁶ Reinhold Ganz with the Bern Hip Group have developed an outstanding open technique using a safe surgical dislocation of the hip to alleviate FAI.^{2,14} An arthroscopic equivalent of the open technique has been developed and performed for 22 months and will be described.²¹ The early results are favorable and may be comparable to the open technique. **Key Words:** Femoroacetabular impingement—Hip arthroscopy—Resection osteoplasty—Femoral head-neck reshaping—Surgical dislocation of the hip.

Hip pain in younger individuals has been associated with abnormal morphology of the hip joint itself. In recent times, there's been more attention paid to acetabular and femoral morphology and its association with femoroacetabular impingement (FAI) syndrome.^{2,14,16,21} FAI may reduce motion because of pain typically in flexion and internal rotation.¹⁵ This is a result of the impinging bump of femoral head-neck bone either overloading the articular cartilage causing chondral injury or delamination defects of the anterior acetabulum with separation and tearing of the adjacent labrum. There are 2 types of FAI: 1) Cam impingement in which there is an increase in the anteriolateral radius of the femoral head mismatching with the radius of the acetabulum; and 2) Pincer impingement in which there is a short offset between the head and the neck allowing the neck to abut against the rim of the acetabulum and labrum.^{2,6,7,13,14} Think of pincer type being similar to a collar on a modular femoral component abutting and deforming the polyethylene cup causing early wear and failure of a total hip.¹ FAI may lead to early degenerative changes and arthritis of the hip if untreated.⁶

MATERIALS AND METHODS

A preliminary study showed that since November 2002 there have been 120 hips done on 118 patients by this surgeon and 38 patients by my associate James M. Glick. The longest follow-up was 22 months. Most patients could not associate an injury to the onset of symptoms. Length of symptoms to time of diagnosis ranged from 3 months to 25 years. The age range was 14 to 73 years, however, the majority were in their 20's to 30's. Pain was mild and annoying in some, not interfering with activities of daily living and work, but made sports impossible to do. Most had the worst pain sitting and couldn't tolerate long car rides, plane trips, or sitting at a desk without taking breaks or slouching to avoid the 90° hip flexed position. Walking or even some running was tolerated. Clicking or occasional popping was common felt in the anterior groin area. Severe acute pain and locking up of the joint was associated with large anterior delamination defects of the acetabulum.

The physical examination showed most had no limp and a negative Trendelenberg test. Range of motion revealed some loss of internal rotation because of pain that was normal under anesthesia. All had a positive impingement sign (pain with flexion and internal rotation) and a small pop could be elicited at the point of maximal pain whereas flexed hip is rolled from maximal

From the Post Street Surgery Center and Total Joint Center at St. Francis Memorial Hospital, San Francisco, California; University of California, San Francisco, San Francisco, California.

Address correspondence and reprint requests to Thomas G. Sampson, MD, 1199 Bush Street, Suite 200, San Francisco, CA. E-mail: tgsampsonmd@msn.com

internal rotation into extension. Resisted straight leg raising was typically nonpainful.

X-ray Analysis

An AP pelvis and AP and frog-leg lateral were done to look for abnormal morphology. A subtle to obvious bump was seen on all at the head neck junction, and some only on the neck. Some showed a retroverted acetabulum with a figure 8 sign.¹⁶ All had good maintenance of the joint space.

An magnetic resonance imaging (MRI) was done on all with many having to be redone because of inadequacy of the first study. ArthroMRIs were also performed especially if either no pathology was seen or if articular defects were suspected. Labral separations from the anterior articular rim or tears were usually seen, and double densities with contrast showed degenerative defects of the articular cartilage or delamination defects. Many had a herniation pit seen below the physal scar at the anterior and lateral junction.^{3,5,18,19}

Surgical Dislocation for FAI

The Bern hip group developed a joint preserving surgical approach to remove the offending bone by reshaping the femoral head neck junction or the acetabular rim.^{2,4,14,17,25,26} To do this safely, they studied the blood supply to the femoral head and found if they preserved the lateral to the epiphyseal branch of the medial femoral circumflex artery, other capsular arteries can be sacrificed without causing avascular necrosis.⁸ The procedure is done with the patient in the lateral decubitus position through a lateral approach to the hip. A trochanteric osteotomy (trochanteric flap) and an anterior dislocation of the hip allows for a 360° view of the head and neck and a good view into the acetabulum. Labral tears maybe treated with partial resection or repair and acetabular rim osteophytes are removed. The head neck may be reshaped and contoured using osteotomies (Figs. 1 and 2).¹⁴

Postoperatively, patients are kept on 2 crutches, non-weight bearing until the trochanteric osteotomy has healed at about 6 weeks.

The goal was to eliminate pain and the pathologic cause of early degenerative joint disease. They studied 19 patients with a mean age of 36 years old²¹⁻⁵² follow-up for an average of 4.7 years (4-5.2 years). They found good results in 14 out of 19 and no osteonecrosis. They concluded that the surgical dislocation with correction of FAI yielded good results in patients with early degenerative changes not exceeding grade 1. It wasn't beneficial to those with advanced degenerative changes or extensive articular cartilage damage.²

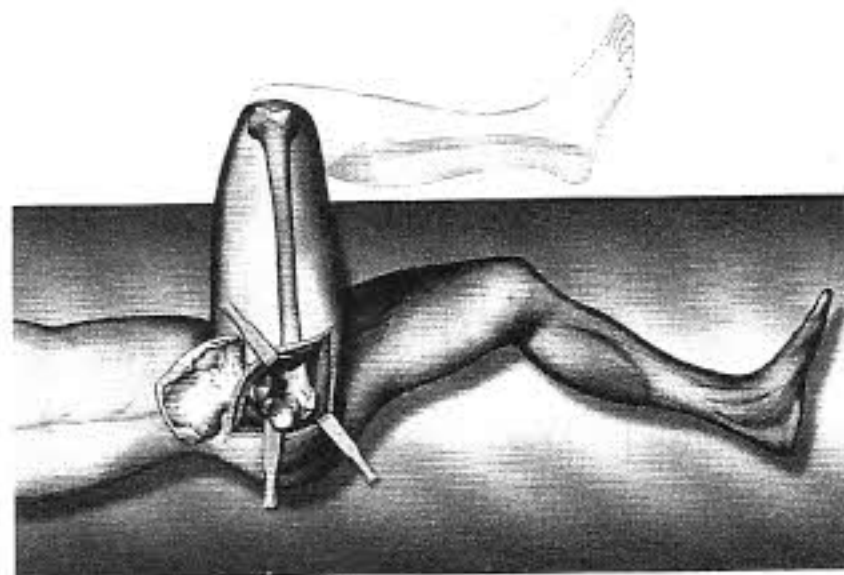


FIG. 1. The drawing shows the exposure with a surgical dislocation allowing full access to the femoral head and acetabulum. Drawings reproduced from Lavigne et al.¹⁴

Reinhold Ganz was of the opinion that the arthroscope may be used for debridement or for labral tears, however, access to the underlying causes of hip impingement was technically challenging if not impossible.¹⁴

It was for that reason, as well as our experience at accessing difficult areas of the hip to remove osteophytes and treat labral tears that we were challenged to create an arthroscopic equivalent to the surgical hip dislocation procedure. It was evident that most of the resection osteoplasty of the femoral head neck junction was done from the mid lateral to anterior and medially.²⁴ It was also evident that an experienced surgeon resected the appropriate amount of bone on the first try.²² It was rare to remove more bone after checking head neck clearance by flexing the hip during the procedure. From that, it was felt that a 360° view of the femoral head neck junction was not entirely necessary. Most of the boney excrescence in FAI is anterior extending lateral. Likewise, most of the acetabular lesions and the exostoses occurred anterior. In addition, most of the labral lesions associated with impingement and the chondral defects of the acetabulum occurred anteriorly with a few extending posteriorly.

Technique of Arthroscopic Treatment of the FAI

The patient is placed in a lateral decubitus position and set up identical to the "lateral approach" (Fig. 3).^{9-11,23} This may be done in the supine position as well. A standard distractor is used, and the peroneal post should be at least 9 cm in diameter. The peroneal post is placed eccentrically toward the operated hip to reduce the chance of a pudental nerve palsy.²⁰ The c-arm fluoroscope is brought in under the table, providing a good anterior to posterior your view orthogonal view (Fig. 4). After the leg is set up in the traction device, the hip is

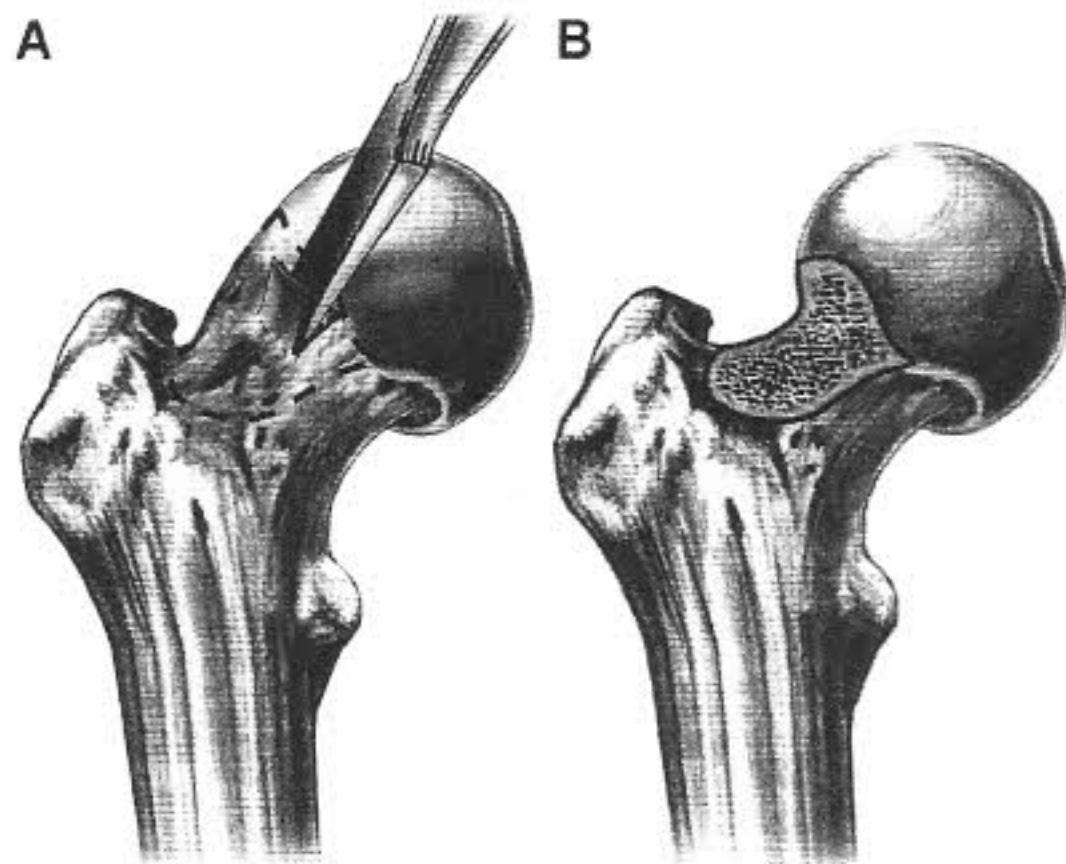


FIG. 2. Resection osteoplasty of the femoral head neck junction (A) before and (B) after, recreating the normal contour.¹⁴

fluoroscoped looking for the minimal offset or flattening of the femoral head neck junction or a lateral bony excrescence. It may appear as a pistol grip deformity.¹² Typically, this is best seen on an AP fluoroscopic image with the hip in maximal external rotation, which rotates the anterior aspect of the femoral head into the field-of-view.

Three standard portals will be used: the posterolateral, anterolateral, and anterior portals.

With adequate distraction, the hip joint is decompressed with a large spinal needle allowing room air to break the suction seal. Using a cannulated system the arthroscope is first introduced in the posterolateral portal with a 30° arthroscope. The anterolateral portal is then

created under direct vision and the hip is first viewed under air followed by fluid.

The hip joint is swept with the arthroscope in the standard fashion. Typical findings in patients with FAI show fraying or tearing of the labrum anteriorly and laterally. There may be anterior acetabular articular cartilage damage from grade 1 to 4 and occasionally extending from mid lateral to posterior. Probing will un-

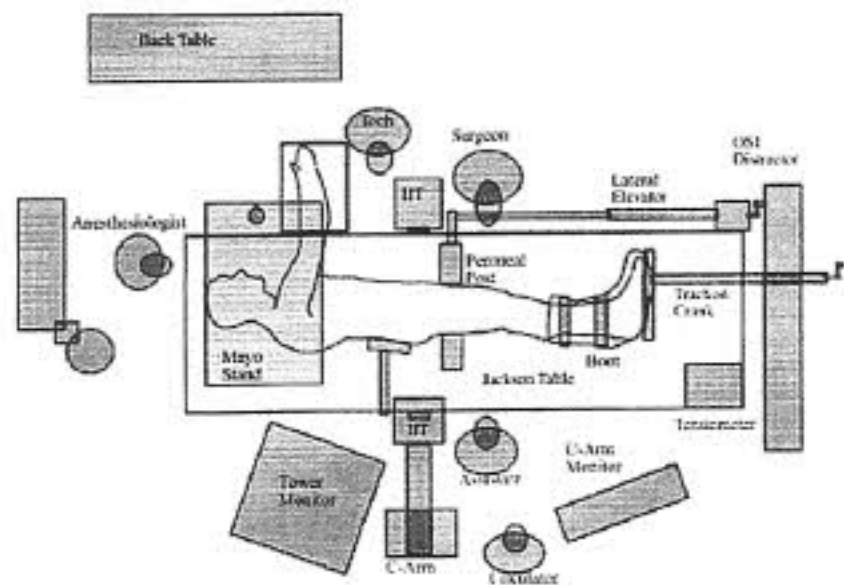


FIG. 3. Room set up. Note the surgeon stands anterior to the patient and the c-arms, brought under the patient.

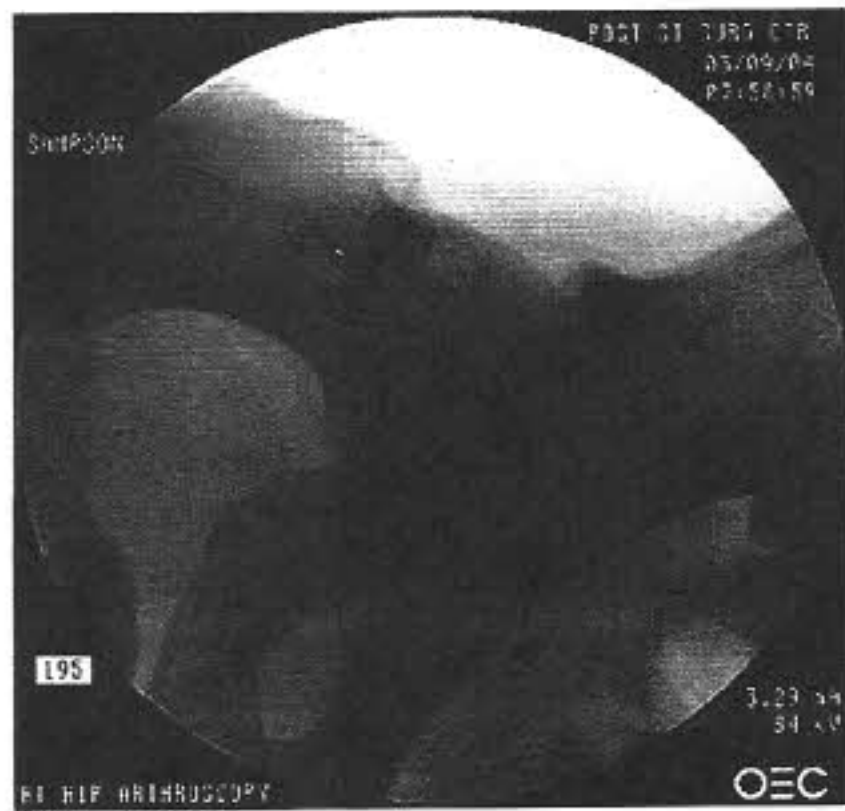

FIG. 4. Orthogonal C-arm fluoroscopic view of a right hip with the leg in external rotation.

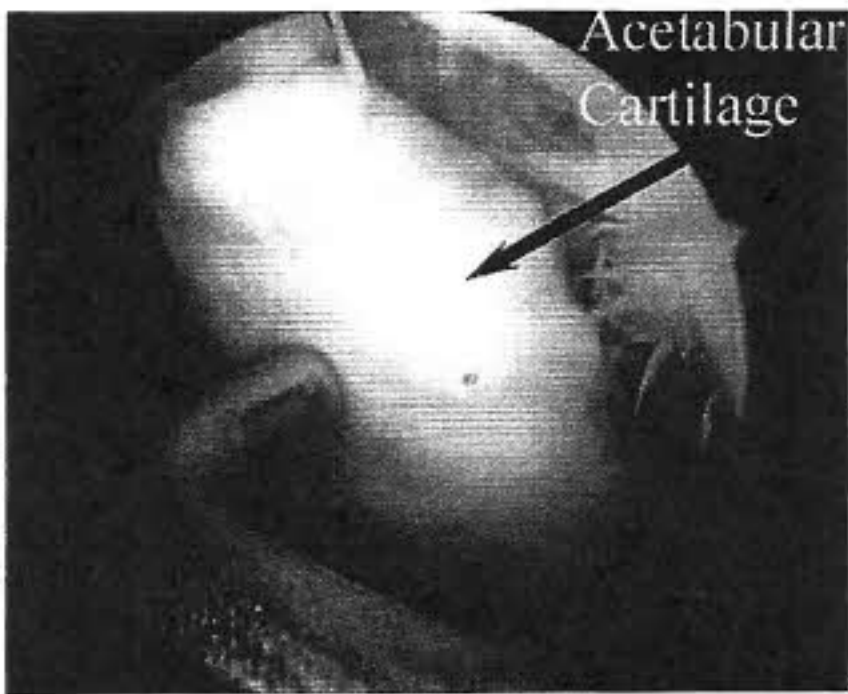


FIG. 5. Probing a delamination defect of the acetabular articular cartilage in a right hip.

cover delamination defects hiding under normal appearing cartilage (Fig. 5).

Labral lesions are debrided with a shaver or a radio-thermal device and the articular cartilage is debrided or smoothed. Delamination defects that are encountered must be debrided back to stable cartilage (Fig. 6A,B). The use of microfracture or picks has been done to stimulate cartilage production. Notch osteophytes are removed with a burr and curettes.

The traction is let down completely while the hip is kept in extension with typical traction times from 12 to 30 minutes. The scope is then placed in the anterolateral portal on the capsule, checked for position with the C-arm and with the trochar the muscle is separated from the capsule (Fig. 7). The anterior portal is then created.²³ The remaining portion of the surgery is done outside the joint while viewing the capsule. The potential space between the muscle and capsule is developed by bringing the shaver to the tip of the arthroscope at the peak of the bump. While under direct vision, the sweeping motion will separate the planes and a workable space is developed.

An anterior capsulectomy is then done with a series of instruments, including a cutting radiothermal device, Beaver blade and the motorized shaver. During this process the foot is maintained in maximal extra rotation to position important retinacular vessels posterior and away from the capsulectomy (Fig. 8). Initially, the procedure was tried using 3 standard portals with the hip in traction and the capsule left intact. We noticed that the majority of the procedure could be done without any traction if the hip was placed in some flexion to open up the capsule, for better viewing. Because of some diffi-

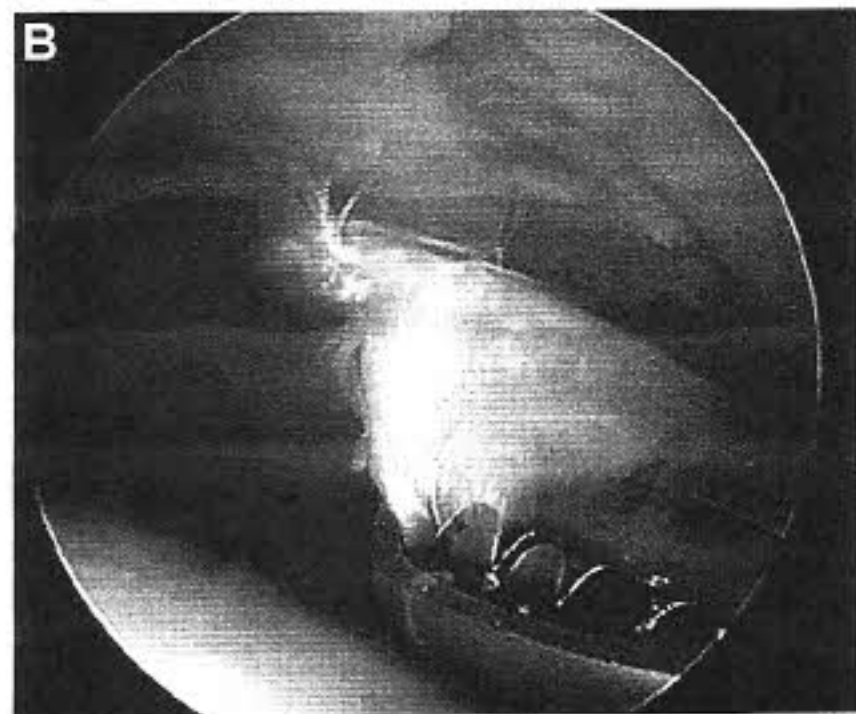
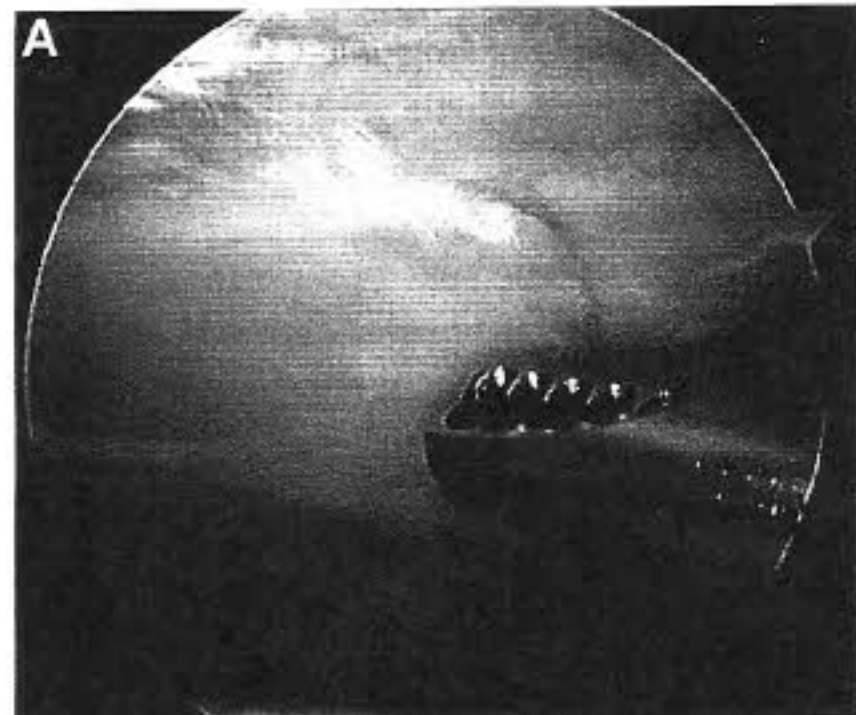

FIG. 6. A young professional bull rider with right sided cam impingement. (A) Arthroscopic view from the anterolateral portal illustrates an element of articular delamination and (B) it being debrided from the posterolateral portal.

culties with exposure we settled on an anterior capsulectomy for the best exposure. On 1 patient, a follow-up MRI showed a brilliant capsular healing response within 6 weeks. There were no problems of instability from the partial capsulectomy.

After exposure of the entire bony bump or osteophyte is accomplished, often a cleft or demarcation at the osseous cartilaginous junction to the femoral head neck junction and the base of the neck is seen (Fig. 9). The capsule may be retracted with a probe to view the external portion of the labrum. The bumpy bone has an appearance of areas of erosion mixed with erythematous grayish irregular surfaces. It neither looks like normal bone, cartilage, or periosteum.

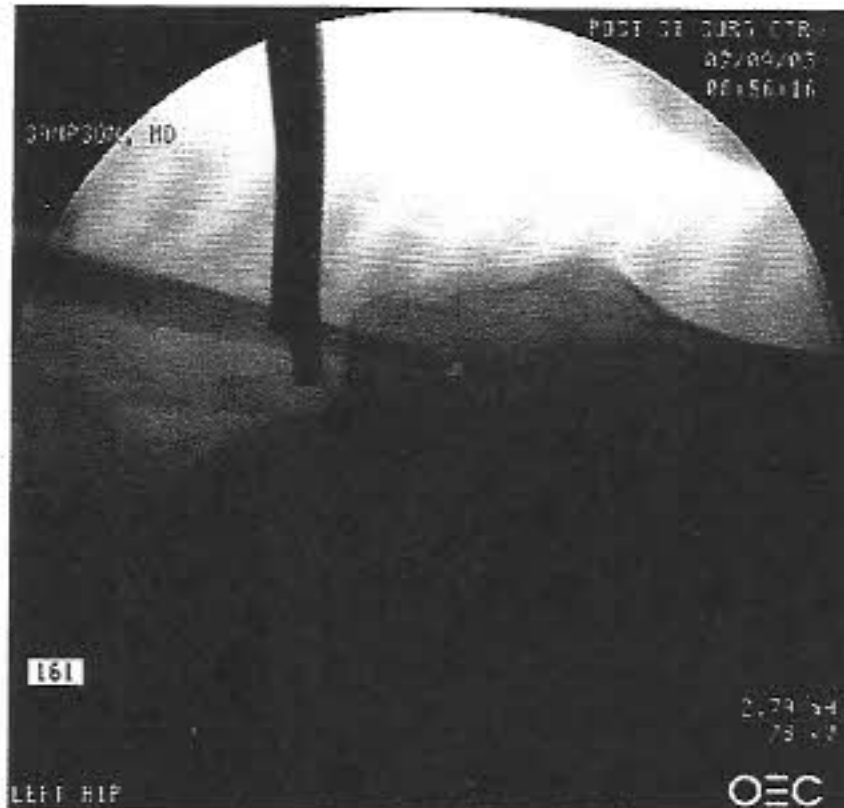

FIG. 7. (A-C) A young professional bronco rider with left sided cam impingement lateral fluoroscopic view demonstrates the probe and scope.

The resection osteoplasty is done with a 4.0 mm or 5.5 mm unhooded round burr. The area of resection is first outlined and then contoured between the outlines. The

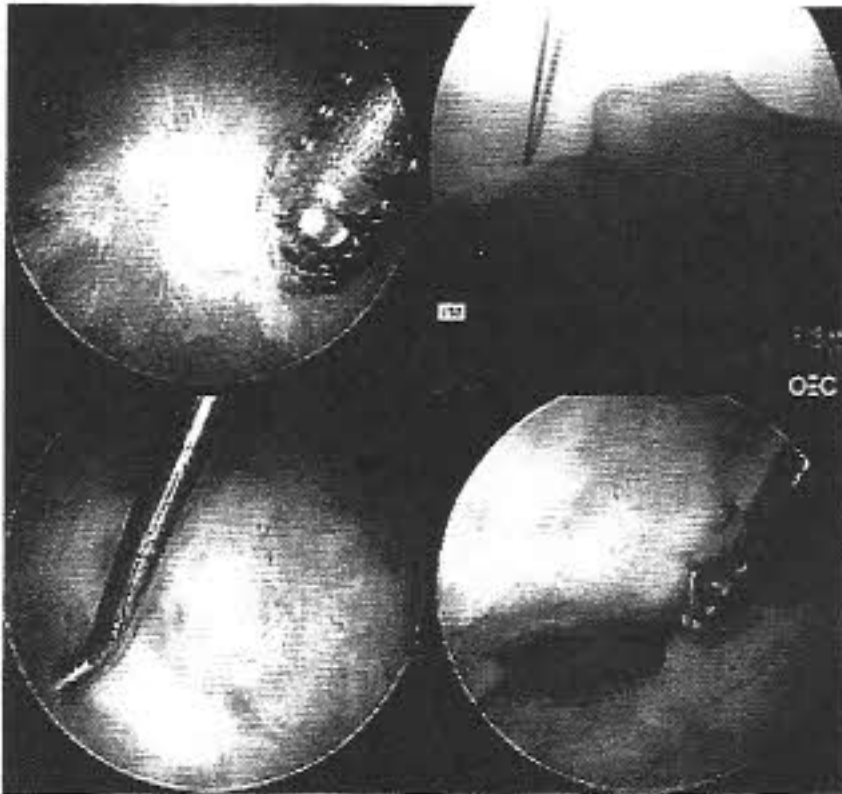


FIG. 8. (A,B) Capsulectomy: Exposure is obtained from the anterior medial to the anterior lateral femoral neck. Upper left shows the shaver outside the left hip capsule with the scope in the anterior portal and the shaver in the anterolateral portal. The upper right is a fluoroscopic view of the shaver and the hip is in maximal external rotation. The bottom left shows a probe at the cleft between normal head cartilage and the hyperemic boney bump. The bottom right is a view into the medial peripheral space.

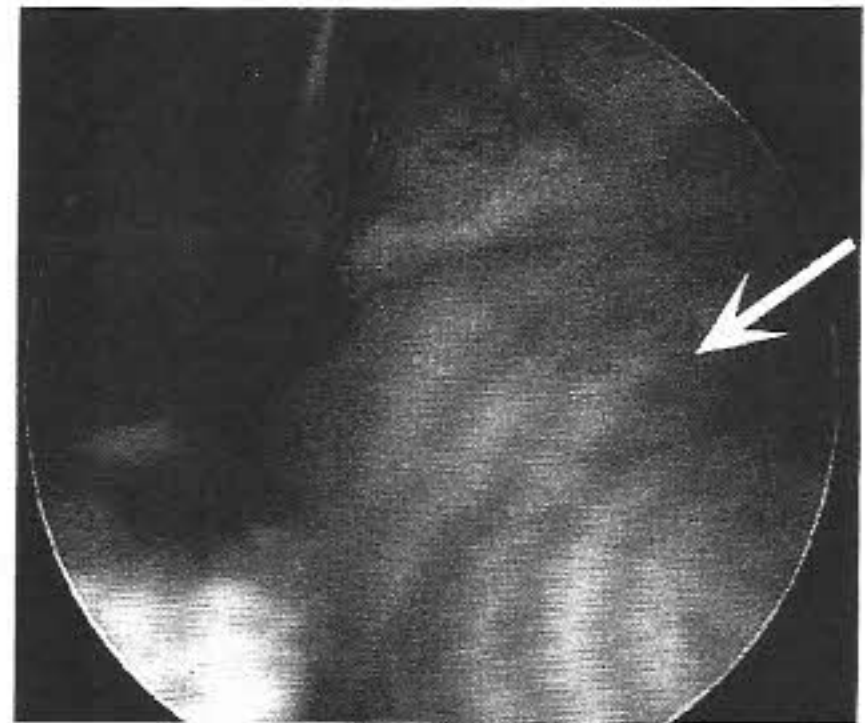


FIG. 9. Shows a cleft (arrow) between the normal articular and abnormal excrescence cartilage in this left hip viewed through the anterior portal.

scope and burr are moved between portals to get a 3-dimensional view. Throughout the procedure, several X-rays are taken using the fluoroscope to ensure that adequate contouring is done and enough bone is resected (Fig. 10A-C). The convex shape of the excrescence is sculpted to a concave shape circumferentially from anterolateral to anteromedial (Fig. 11A,B).

Finally, the leg is detached from the traction device and put through a range of motion with direct viewing from the arthroscope, to document clearance at the head/neck junction and the acetabular rim.

If there is an acetabular rim osteophyte, this may be resected in the same fashion behind the intact labrum. Occasionally, the labrum must be excised. To date we have not detached the labrum to remove a rim osteophyte and then done a labral repair.

Postoperatively, the patients are placed on 2 crutches for protected weight bearing and fall prevention. They are allowed to shower the next day and come off crutches from 2 to 4 weeks when they feel they are stable. They are instructed to not engage in any sporting activities or excessive activities for 1 month. They may begin range of motion exercises such as the use of the stationary bicycle or swimming. At 1 month, the activity level is increased and physical therapy is used if their range of motion is poor. By 3 months all restrictions are removed.

RESULTS

Since November 2002, 120 patients by this surgeon and 38 by my associate James M. Glick had undergone

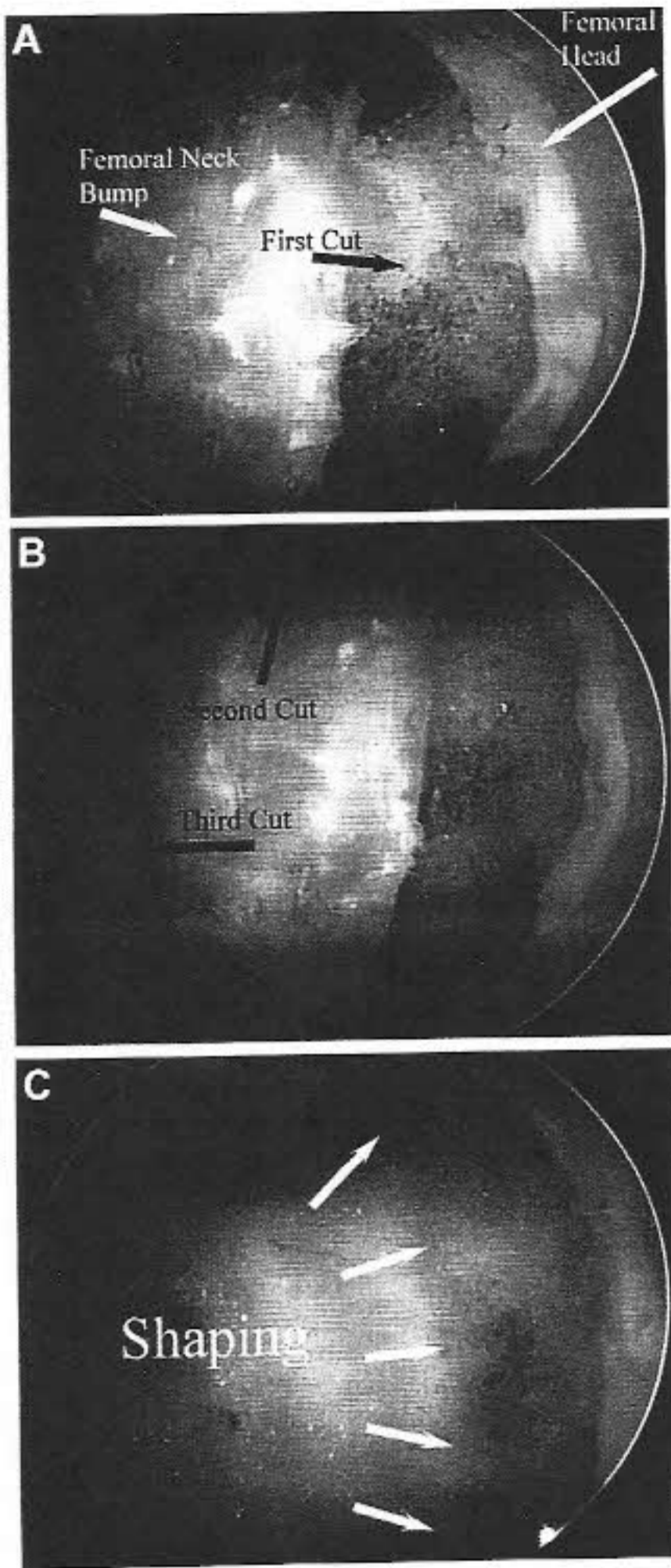


FIG. 10. Resection osteoplasty (A) outlining and cutting the trough on a right femoral head neck junction near the articular margin and (B) continuing the lateral then inferior cuts followed by contouring and shaping between the outlines with an arthroscopic burr looking through the anterolateral portal. The 4.0 mm burr comes through the anterior portal.

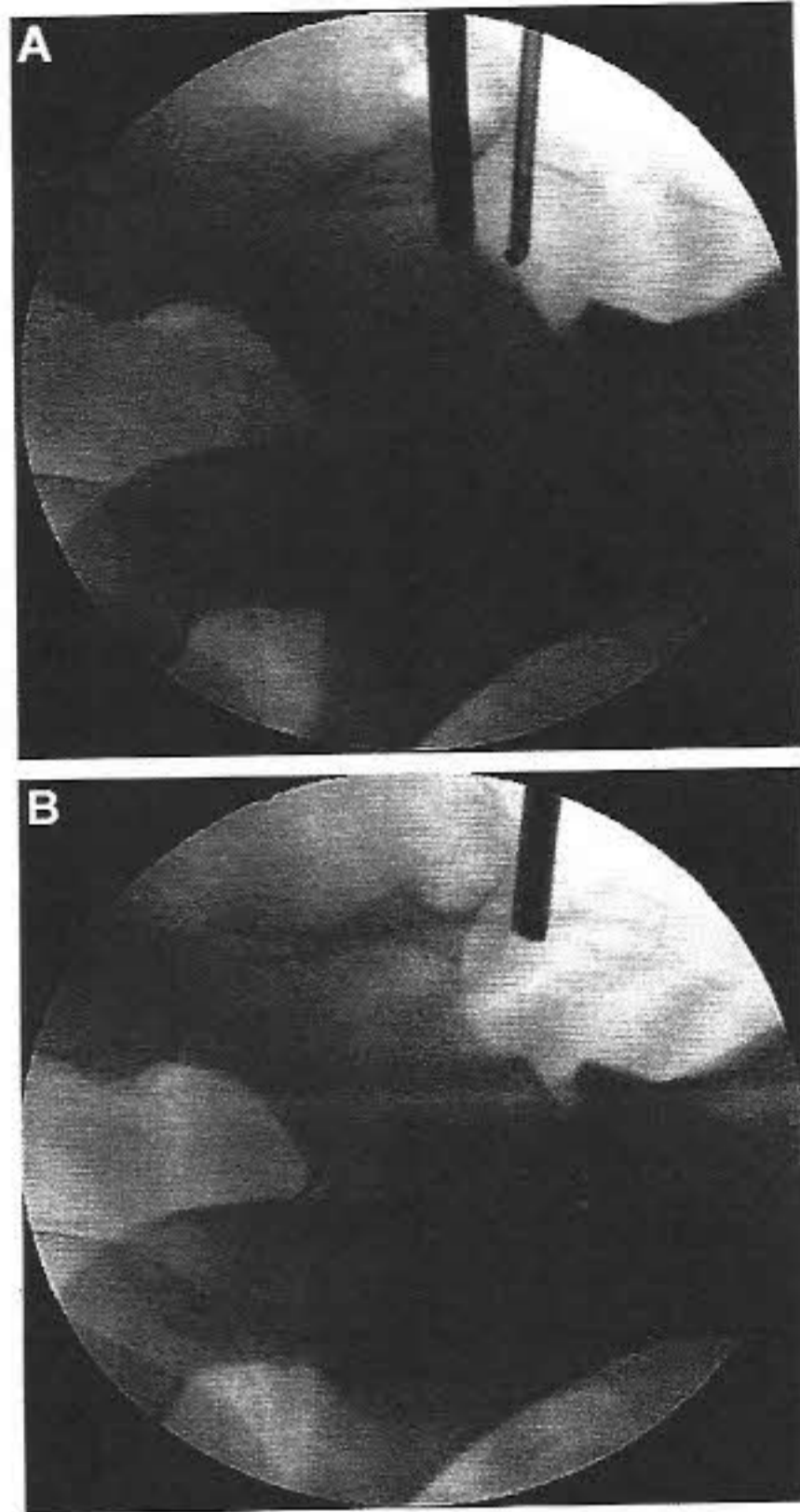


FIG. 11. AP fluoroscopic images showing (A) preresection osteoplasty and (B) postresection in this right hip.

arthroscopic treatment for FAI. Our preliminary experience has been that nearly all patients had elimination of their impingement sign (pain on internal rotation and flexion of the hip) and were quite happy with their results. Three patients went on to have total joint replacements. The poorer results seemed to correlate with the amount of damage to the articular surfaces seen at arthroscopy many times undetected by imaging studies. The greater damage ($>$ grade 3 chondromalacia or delamination defects) resulted in poorer outcomes and/or longer recovery time. We found in the majority 50% of

pain was gone from 6 weeks to 3 months, 75% by 5 months and 95% by 1 year. The early results seem to be similar to those reported in the open dislocation procedure and patients were off their crutches within 2 to 4 weeks.

One patient suffered a pathologic fracture, which was nondisplaced and required a closed pinning. There were no other complications.

CONCLUSION

FAI occurs in late adolescents and young adults and may be a precursor to early hip arthritis.

Reinhold Ganz and his Bern Hip Group and Jeff Mast have made significant contributions to our understanding of FAI. They have demonstrated that its early correction may alleviate pain and prevent the progression of arthritis of the hip.

An arthroscopic equivalent to the open surgical dislocation has been presented. Our experience has shown it can be done safely and effectively with favorable early results. Patients are off crutches quickly and no hardware is left behind as with the trochanteric osteotomy done in the open procedure. Only after a thorough study will we be able to compare the long-term outcome with those of the open procedure, however, the early results are very favorable and the less invasive procedure is more desirable.

ACKNOWLEDGMENTS

The author thanks James M. Glick for his ideas and contributions. Jeffrey W. Mast for allowing the author to observe his techniques.

REFERENCES

1. Barrack RL, Burke DW, Cook SD, et al. Complications related to modularity of total hip components. *J Bone Joint Surg Br* 1993;75:688-692.
2. Beck M, Leunig M, Parvizi J, et al. Anterior femoroacetabular impingement: part II. Midterm results of surgical treatment. *Clin Orthop* 2004;Jan:67-73.
3. Daenen B, Preidler KW, Padmanabhan S, et al. Symptomatic herniation pits of the femoral neck: anatomic and clinical study. *AJR Am J Roentgenol* 1997;168:149-153.
4. Eijer H, Myers SR, Ganz R. Anterior femoroacetabular impingement after femoral neck fractures. *J Orthop Trauma* 2001;15:475-481.
5. Freedman Y, Tal S. Synovial herniation pits: a pseudo-lesion of the femoral neck. *Isr Med Assoc J* 2004;6:189.
6. Ganz R, Parvizi J, Beck M, et al. Femoroacetabular impingement: a cause for osteoarthritis of the hip. *Clin Orthop* 2003;Dec:112-120.
7. Garbuz DS, Masri BA, Haddad F, et al. Clinical and radiographic assessment of the young adult with symptomatic hip dysplasia. *Clin Orthop* 2004;Jan:18-22.
8. Gautier E, Ganz K, Krugel N, et al. Anatomy of the medial femoral circumflex artery and its surgical implications. *J Bone Joint Surg Br* 2000;82:679-683.
9. Glick JM. Hip arthroscopy using the lateral approach. *Instr Course Lect* 1988;37:223-231.
10. Glick JM. Hip arthroscopy. The lateral approach. *Clin Sports Med* 2001;20:733-747.
11. Glick JM, Sampson TG, Gordon RB, et al. Hip arthroscopy by the lateral approach. *Arthroscopy* 1987;3:4-12.
12. Harris WH. Etiology of osteoarthritis of the hip. *Clin Orthop* 1986;Dec:20-33.
13. Ito K, Minka MA, 2nd, Leunig M, et al. Femoroacetabular impingement and the cam-effect. A MRI-based quantitative anatomical study of the femoral head-neck offset. *J Bone Joint Surg Br* 2001;83:171-176.
14. Lavigne M, Parvizi J, Beck M, et al. Anterior femoroacetabular impingement: part I. Techniques of joint preserving surgery. *Clin Orthop* 2004;Jan: 61-66.
15. Leunig M, Podeszwa D, Beck M, et al. Magnetic resonance arthrography of labral disorders in hips with dysplasia and impingement. *Clin Orthop* 2004;Jan:74-80.
16. Mast JW, Brunner RL, Zebrack J. Recognizing acetabular version in the radiographic presentation of hip dysplasia. *Clin Orthop* 2004;Jan:48-53.
17. Myers SR, Eijer H, Ganz R. Anterior femoroacetabular impingement after periacetabular osteotomy. *Clin Orthop* 1999;Sep-Oct:93-99.
18. Nokes SR, Vogler JB, Spritzer CE, et al. Herniation pits of the femoral neck: appearance at MR imaging. *Radiology* 1989;172:231-234.
19. Pitt MJ, Graham AR, Shipman JH, et al. Herniation pit of the femoral neck. *AJR Am J Roentgenol* 1982;138:1115-1121.
20. Sampson TG. Complications of hip arthroscopy. *Clin Sports Med* 2001;20:831-835.
21. Sampson TG. Hip morphology and its relationship to pathology-dysplasia to impingement. *Tech Sports Med* 2004.
22. Sampson TG. Observation and personal communication with Jeff Mast. Edited, 2003.
23. Sampson TG, Fargo LA. Hip arthroscopy by the lateral approach: technique and selected cases. In: Byrd JW, ed. New York: Thieme Medical Publishers, Inc., 1998:105-121.
24. Sampson TG, Glick JM. Experience with the amount of resection osteoplasty of the femoral head neck junction for femoroacetabular impingement. Edited, 2003.
25. Siebenrock KA, Schoeniger R, Ganz R. Anterior femoro-acetabular impingement due to acetabular retroversion. Treatment with periacetabular osteotomy. *Bone Joint Surg Am* 2003;85-A:278-286.
26. Siebenrock KA, Wahab KH, Werlen S, et al. Abnormal extension of the femoral head epiphysis as a cause of cam impingement. *Clin Orthop* 2004;Jan:54-60.